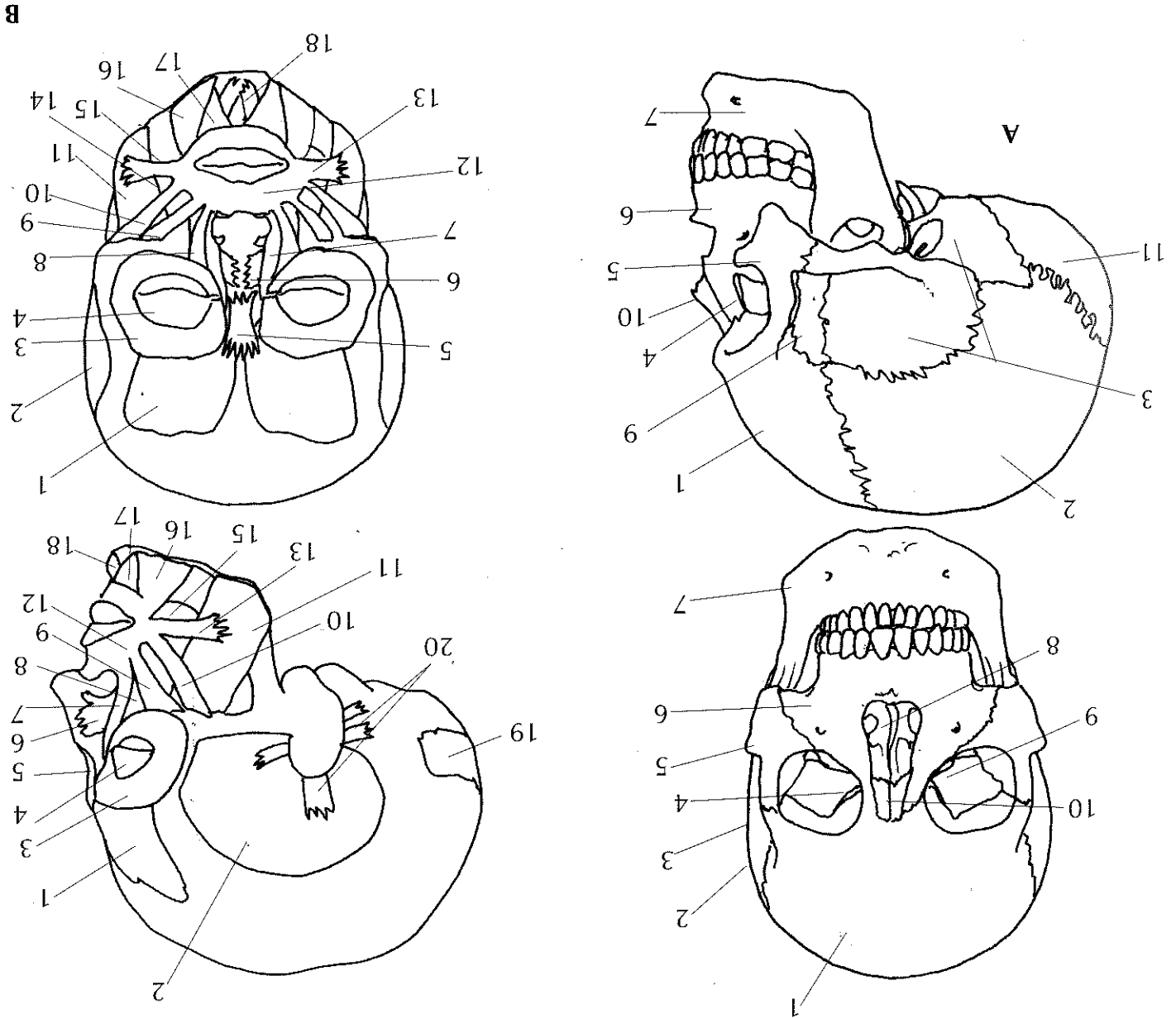


Views of the cranium (A) and of the main superficial muscles (B).



A Bones

- 1 frontal bone
- 2 parietal bone
- 3 temporal bone
- 4 lacrimal bone
- 5 zygomatic bone
- 6 maxilla
- 7 mandible (jawbone)
- 8 vomer
- 9 sphenoid
- 10 nasal bone
- 11 occipital bone

B Muscles

- 1 occipitofrontalis
- 2 temporal fascia
- 3 orbicularis oculi (and 4)
- 5 procerus
- 6 nasalis muscle
- 7 levator labii superioris
- 8 levator labii superioris (intraorbital)
- 9 zygomaticus minor
- 10 zygomaticus major
- 11 masseter
- 12 orbicularis oris
- 13 risorius muscle
- 14 levator anguli oris
- 15 buccinator muscle
- 16 triangularis
- 17 quadratus labii inferioris
- 18 mentalis
- 19 occipitalis
- 20 auricular muscles